

The Use of Platelet-Rich Plasma in the Management of Foot and Ankle Conditions

Xiaofeng Jia, MD, PhD,^{*,†} Paul G. Peters, MD,[‡] and Lew Schon, MD^{*,‡}

Platelet-rich plasma (PRP) contains growth factors derived from venous blood. Bone marrow concentrate (BMC) is an analogous platelet-rich product that is generated from bone marrow aspirate and might have the added advantage of containing mesenchymal stem cells. The active growth factors are platelet-derived growth factor, transforming growth factor β , vascular endothelial growth factor, hepatocyte growth factor, fibroblast growth factor, and epidermal growth factor. It is probable that a multitude of factors and cells play a role in inducing healing of hard or soft tissues that have been acutely or chronically injured or diseased. PRP can be used alone or in conjunction with surgical reconstruction to achieve better healing of tissues. Our group has treated 634 patients with PRP or BMC for nonunions, malunions, arthritis, malalignments, tendinopathies, tendon ruptures, plantar fasciitis, fractures, or ligament injuries that were performed in a variety of healthy and unhealthy patients. Overall, the results were favorable with very limited morbidity. In general, healing was more complete and rapid compared with historic norms, but failures can still occur. Condition-specific retrospective and prospective studies are underway to further establish the role of PRP in foot and ankle conditions and reconstructions.

Oper Tech Sports Med 19:177-184 © 2011 Elsevier Inc. All rights reserved.

KEYWORDS bone marrow aspiration, bone marrow concentrate, foot and ankle, growth factor, mesenchymal stem cells, musculoskeletal, platelet-rich plasma

Platelet-rich products can be obtained from autologous blood (platelet-rich plasma [PRP]) or bone marrow aspirate via concentration of the platelets/white blood cells and removal of the red blood cells and platelet-poor plasma (PPP). According to Welch et al,¹ bone marrow aspirate contains a similar concentration of platelets as peripheral blood. Although bone marrow itself does not contain a high number of platelets, it is common to have some level of peripheral blood dilution during marrow aspiration. This is evident with the approximately 1×10^6 platelets/ μL found in the bone marrow concentrate.¹ In addition, the percentage recovery of available platelets (81.3%) is similar to reports for blood-derived PRP.² The magnitude of the concentration depends on the preparation systems. The clinical use of PRPs

has been reported for a wide variety of applications, most prevalently during maxillofacial surgery to accelerate peri-implant soft tissue and bone healing,³⁻⁹ for healing problematic wounds,¹⁰⁻¹⁴ sports medicine indications,¹⁵⁻²⁰ spine surgeries,²¹ and recently in foot and ankle injuries.^{10,11,16,22-25} It has been investigated for soft-tissue repair and the regeneration of bone, cartilage, fascia (Fig. 1), tendon (Fig. 2), and ligaments. Using cell-separating systems, PRP provides various critical growth factors that participate in tissue-repair processes. However, the data in soft tissue in the foot and ankle are mixed. A controlled study evaluating PRP injections in chronic Achilles tendinopathy failed to show significance.²⁶ Criticisms of this study included the following: it was underpowered, a short follow-up, nonchronic injury inclusion, PRP was delivered by bolus injection rather than a peppering delivery, and there was a lack of controlled rehabilitation.²⁶ Recently Monto²⁷ presented his results of Achilles tendinopathy and reported improvements from the baseline conditions. Gaweda et al²⁸ noted an improvement in their prospective evaluation of Achilles tendinopathy treated with PRP. Sanchez et al²⁹ reported that in athletes undergoing Achilles tendon repair, PRP supplementation was associated

*Department of Biomedical Engineering, Johns Hopkins University, School of Medicine, Baltimore, MD.

†Department of Physical Medicine and Rehabilitation, Johns Hopkins University, School of Medicine, Baltimore, MD.

‡Orthopedic Surgery Department, Union Memorial Hosp, Baltimore, MD. Address reprint requests to Xiaofeng Jia, MD, PhD, 720 Rutland Ave, Traylor Bldg 710, Johns Hopkins University School of Medicine, Baltimore, MD 21205. E-mail: xjia1@jhmi.edu

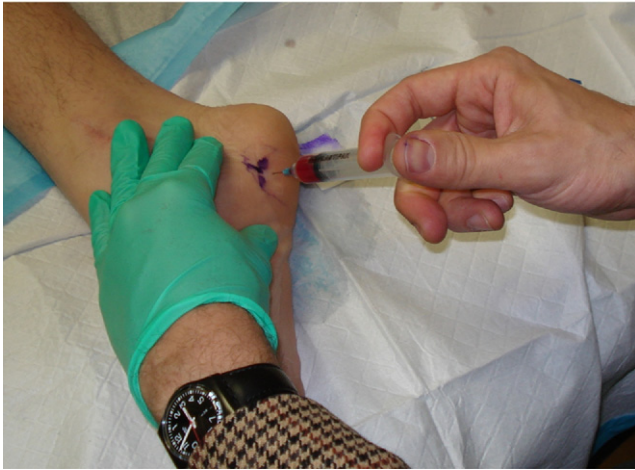

Figure 1 The injection of PRP into plantar fascia.

with a quicker return of motion, running, and training as well as less scar tissue as retrospectively compared with a matched group. This study was contradicted by Schepull et al³⁰ who found that there was no improvement in elasticity modulus or heel raise index with a lower Achilles tendon total rupture score in the PRP group.

Bone marrow aspirate can be concentrated using very similar techniques, with the concentrated solution containing mesenchymal stem cells (MSCs), hematopoietic stem cells (HSCs), endothelial progenitor stem cells (EPCs), and other progenitor cells.³¹ The cells have roles independently and in combination with each other to initiate and maintain a healing response. They secrete trophic, paracrine, and growth factors that are immunomodulatory, profibrotic, and promote angiogenesis and hematopoiesis, which are all important factors in the wound-healing process.³² In addition, they have the ability to differentiate, and they help establish new vascular and musculoskeletal tissues.³³

Bone marrow concentrate (BMC) is also used for a broad spectrum of clinical applications, such as spine surgery,³⁴⁻³⁶ simple bone cysts,³⁷⁻³⁹ and fracture delayed union or non-

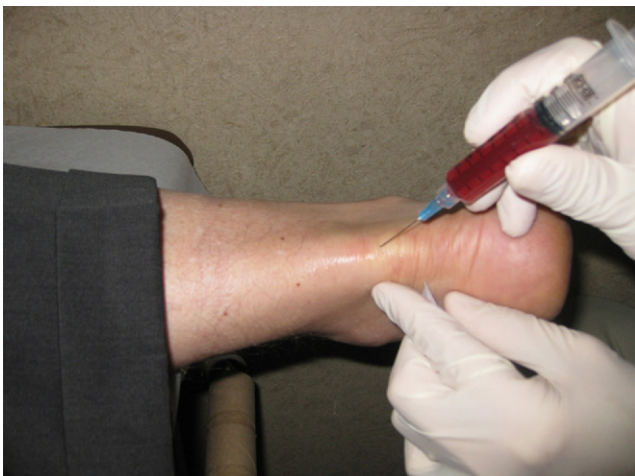

Figure 2 The injection of PRP into noninsertional Achilles tendinopathy.

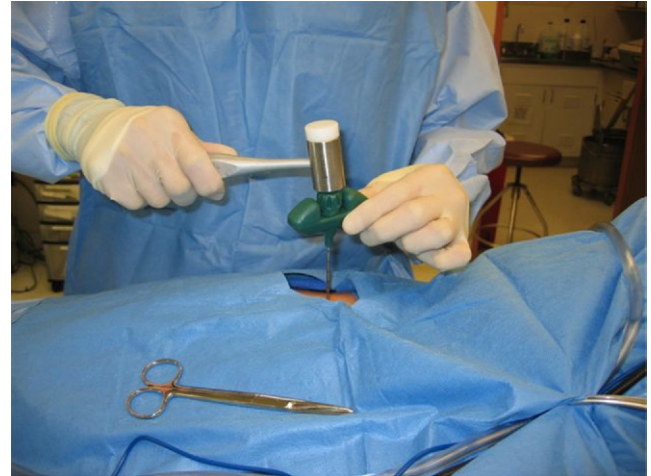


Figure 3 The harvest of bone marrow aspiration from the iliac crest.

union.⁴⁰⁻⁴⁹ However, foot and ankle BMC studies are limited. Pinzur⁵⁰ investigated the use of PRP and unconcentrated bone marrow aspirate in 44 high-risk diabetic patients with Charcot foot arthropathy. Bony union was obtained in 42 of 46 feet at 26.2 ± 12.2 months, concluding that PRP and BMA had comparable results to autologous cancellous bone grafting. BMC application in chronic ulcer treatment especially in the ischemic limb has shown some benefit.^{51,52} Finally, the treatment of osteochondral lesions with BMC has shown promising results with an improved American Orthopaedic Foot and Ankle Society score at a minimum 24-month follow-up in 48 patients.⁵³

Growth Factors in PRP

PRP contains various growth factors that play important roles in cell proliferation, chemotaxis, cell differentiation, and angiogenesis concentrations. The basic cytokines identified include platelet-derived growth factor, transforming growth factor β , vascular endothelial growth factor, hepatocyte

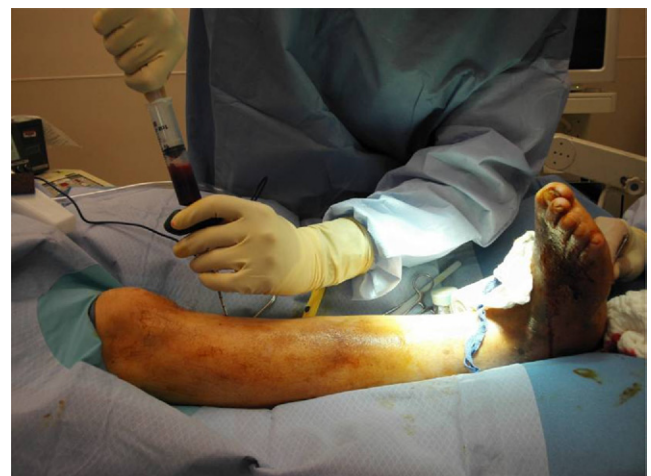

Figure 4 The harvest of bone marrow aspiration from the medial tibia.

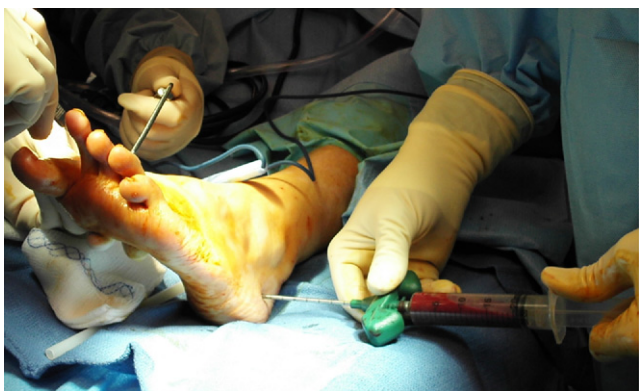

Figure 5 The harvest of bone marrow aspiration from the calcaneus.

growth factor, fibroblast growth factor, epidermal growth factor, and endothelial cell growth factor. The clinical benefit of these growth factors contained in PRP or BMC for the treatment of pathologies of the foot or ankle is derived from these biological properties. The molecular mechanisms of action and preclinical studies supporting the use of these growth factors is covered elsewhere in this special edition of *Operative Techniques in Sports Medicine* and therefore will not be reviewed herein.

PRP/BMC Collection and Processing

Two different sources for platelet concentrate can be used. Traditionally, autologous blood is obtained from a peripheral blood draw and mixed with various anticoagulants (eg, anticoagulant citrate dextrose solution A (ACD-A)). Volumes are based on technique, technology, quality, and quantity desired (10-120 mL). Alternatively, bone marrow aspiration can be obtained from any of the standard autograft locations, (eg, iliac crest, proximal/distal tibia, or calcaneus) mixed with anticoagulants and processed. Centrifugation is then typically used to generate PRP or BMC. One difference between PRP and BMC is that BMC is a source of nucleated cells including (eg, MSCs, HSC, EPCs, and other progenitor cells).^{1,31} The mechanism of the therapeutic effect is uncertain, but numerous growth factors and cytokines have been studied. The role of MSCs and HSCs derived from human adult bone marrow on the healing of these tissues has been studied and evidence supports the role for both cell types.^{33,46,54,55}

Technique of Harvesting

At the time of the surgery for the underlying foot or ankle disorder, bone marrow aspiration is performed from the anterior iliac crest, proximal tibia, or lateral calcaneus. The method used has been described by Hernigou et al.^{45,46} With carefully drawing out of 4-mL aliquots and then repositioning the needle, $2,579 \pm 1,121$ progenitors/cm³ (range, 60-6,120 progenitors/cm³) can be concentrated.⁴⁶

Iliac Crest

Typically, a bump, bean bag, or folded sheets are placed under the hemipelvis. This brings the anterior ilium forward and shifts the abdominal tissues toward midline and away from the site. The anterior superior iliac spine is palpated, and beginning 3 to 5 cm proximal to this point, a cannula/trochar system is used. Through a 2- to 3-mm incision, the surgeon palpates the inner and outer table of the iliac wing, and the harvesting trochar perforates the bone between the tables. The trochar is advanced 4 cm manually or more routinely with the assistance of a mallet (Fig. 3). Next, the trochar is removed, and a 30-mL syringe filled with 4 mL of ACD-A is connected to the threaded end of the cannula. Aspiration of 2 to 4 mL is performed while rotating the cannula. The cannula is then withdrawn 1 cm, and another 2 to 4 mL of bone marrow is aspirated. This process of withdrawing and rotating the harvest device after aspiration of 2 to 4 mL continues until the cannula's side perforations are no longer within the bone. The syringe is detached and gently mixed by multiple inversions with the ACD-A so the aspirate does not coagulate. Next, the harvest device is repositioned deeply at another angle while still maintaining orientation between the 2 bone tables. For a standard lower-leg or foot procedure, 30 to 60 mL is harvested (actually 26 mL or 54 mL of bone marrow aspirate plus the 4 mL or 8 mL of ACD-A).

Proximal Tibia

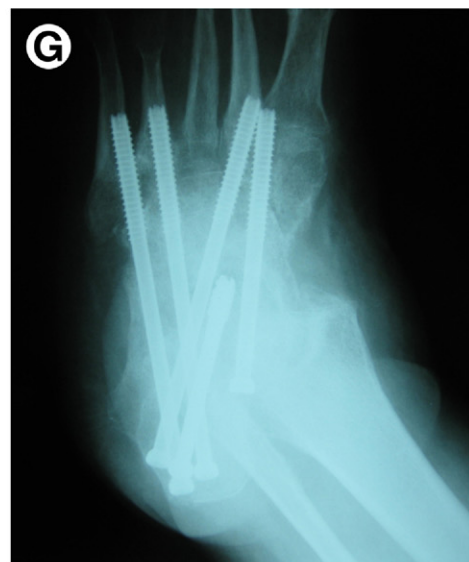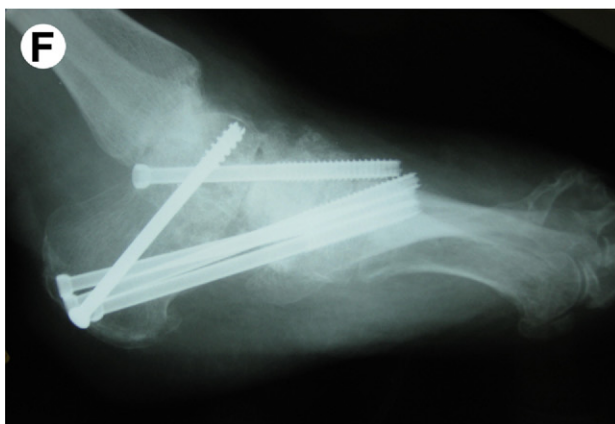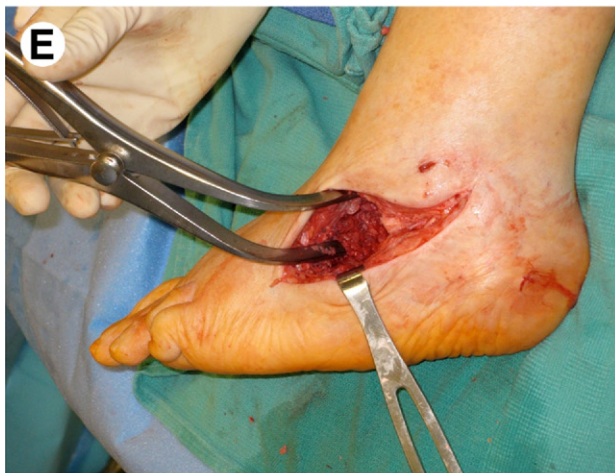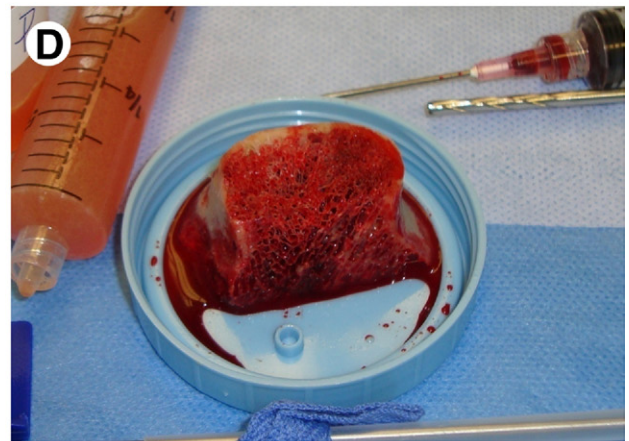
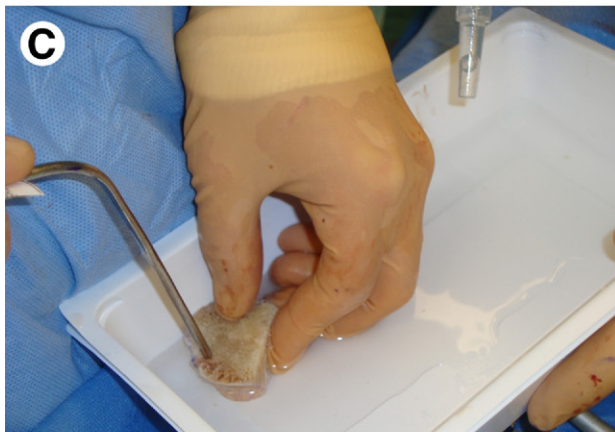
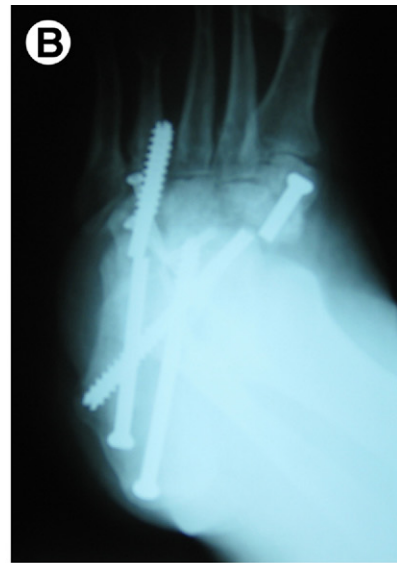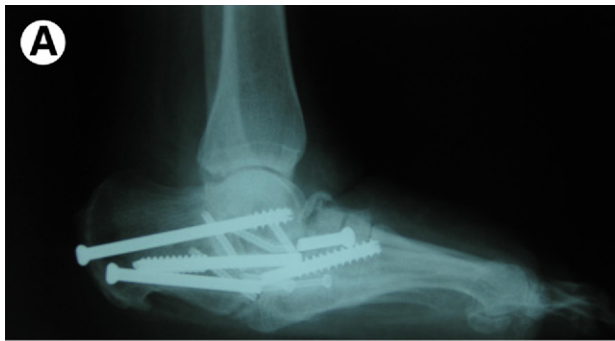The tibia will be selected if the patient has pendulous abdomen that precludes palpation of the pelvic landmarks which is necessary for a safe pelvic aspiration (Fig. 4). It is also indicated if the patient is unable to be adequately sedated for a comfortable harvest. Another indication is to avoid contaminated tissues. We have found that the cell count here is 40% of the iliac crest but that the growth factors were at a similar concentration (Bae SY and Schon LC, unpublished data, 2008). The joint line is palpated as is the boundaries of the medial face of the tibia. A 2- to 3-mm incision is made 3 to 4 cm below the joint. The method of withdrawal is the same as mentioned earlier.

Lateral Calcaneus

An alternative to iliac crest and proximal tibia is the lateral calcaneus. This site is chosen when only 30 mL of aspirate is needed, typically for a mid- or forefoot procedure (Fig. 5). The 2- to 3-mm incision is made over the tuberosity posterior to the sural nerve territory, approximately one quarter of the way between the posterior aspect of the heel and the tip of the fibula. The trochar assembly is introduced manually frequently without the need of the mallet, perpendicular to the bone and penetrated 2 to 3.5 cm. Aspiration is performed as described earlier.

Delivery

According to the authors' preferred technique based on clinical experience, administration is based on the chronicity,



location, and pathology. PRP from peripheral blood is used primarily in the clinic/office setting, and BMC is used in the operative suite. We have used PRP in the office setting to successfully treat a broad spectrum of conditions, including chronic fasciitis and tendinopathy. Plantar fasciitis and mid-substance and insertional Achilles tendinopathy predominate. Other tendons that we have treated include tibialis posterior, peroneal tendons, tibialis anterior, extensor digitorum longus, and metatarsal phalangeal joint ligaments. Successful case selection begins with structures that have mechanical integrity and are not elongated beyond efficacy. In general, the typical case for PRP treatment is one in which the standard conservative treatment has failed (eg, relative rest, avoidance of the offending activities, bracing, stretching, physical therapy, and anti-inflammatory medications), and surgery is being considered. Some of these conditions have also been considered for extracorporeal shockwave treatment or have undergone a course of this modality. Currently, we do not have any insight as to whether PRP is better than extracorporeal shockwave treatment.⁵⁶

Our technique in the office setting first involves mapping out the areas of maximal tenderness. The skin is prepped, and a local field block is then performed. The pH-buffered PRP is injected using a 25-G needle with a “peppering” technique in which multiple penetrations of the tendon or fascia are performed while placing small amounts throughout the extent of the affected area. We speculate that the multiple penetrations create localized zones of trauma without seriously compromising the mechanical integrity of the tendon or fascia. The coupling of the controlled “injury” and the triggering of the healing cascade with the PRP or BMC instigates cellular responses and tissue repair. Based on the affected area, patients are instructed to wear a boot brace for hindfoot and ankle conditions or a postoperative shoe for midfoot and forefoot conditions. The immobilization of the foot and or ankle is throughout the day with instructions for removal several times daily to perform range-of-motion exercises and weight-bearing dorsiflexion of the ankle 5 times a day for 20 minutes. The bracing is often recommended for 6 weeks but may be used for 3 to 12 weeks. Patients are informed that there will be a flare of pain that can last for 2 weeks but should settle down by 6 weeks. Healing, based on self-reported relief and function, coupled with clinical examination can take 3 months so activities are gradually reintroduced as tolerated.

BMC is used within the operative suite because of the discomfort associated with bone marrow aspiration. Our indications have expanded from delayed unions and non-unions to at-risk fractures (eg, pilons, calcaneal, and an ankle with associated deltoid injury), acute chronic tendon injuries, and arthrodesis cases. Additional indications include compromised hosts, patients with multiple comorbidities, complex cases with multiple independent fusions, osteotomies, or tendon/ligamentous procedures.

For bone-healing purposes, the bone graft (ie, autograft, allograft, or synthetic depending on the indication) is soaked in PRP. BMC can be infused (soaked) into demineralized bone matrix (DBM) (about 1.5 mL PRP to 5 mL DBM) or structural allograft (femoral head) or autograft to serve any need. This will be inserted into the bone or arthrodesis site just before wound closure after final irrigation has been completed. If PRP is used for tendon healing or if there is a nonunion without a void, PRP can be injected via an 18-G needle into the tissue envelop (eg, synovial sheath and periosteal sleeve) once the deep tissues are closed. During injection, a dry field achieved through hemostasis, tourniquet, and the use of the Trendelenburg position is advantageous to minimize the additional egress of fluids that may limit the volume of fluid injected. Thrombin can be used to generate a PRP gel/clot, but this gel state is difficult to attain with BMC in our experience, so thrombin is not used with BMC in our clinical applications. In addition, there have been studies that have suggested that using the thrombin increases the rate of growth factor release and decreases its efficacy in enhancing bone healing.⁵⁷ Finally outside of the United States, bovine thrombin is generally not available, and the more expensive recombinant thrombin is used. As an alternative to exogenous thrombin, kits are available to generate thrombin from the patient’s venous blood. To minimize runoff of BMC from the desired location, it is injected with an 18-G needle at a location away from the incision in the desired location and slowly administered to minimize extravasation.

Clinical Case Experience

Over the last 4 years, 634 cases have been performed using PRP and/or BMC for foot and ankle problems. These cases are being clustered according to diagnosis and treatment for as-

Figure 6 (A) A lateral radiograph of a patient with diabetic Charcot neuroarthropathy that failed a prior attempt at hindfoot fusion for the correction of a rockerbottom deformity with broken hardware, nonunion, malunion, and new midfoot arthritis and collapse. (B) An oblique radiograph of the same patient. (C) After removing the broken hardware, realigning the foot, revising the triple arthrodesis, and preparing the midfoot joints for fusion, the femoral head allograft is washed meticulously removing any remaining marrow elements. (D) The graft is then soaked with bone marrow concentrate while the void/recipient site is prepared for the fusion. (E) The recipient site is contoured to receive the structural graft. (F) The 3-month lateral radiograph showing good graft incorporation with fusion of the hindfoot, 4th and 5th cuboid, and the second metatarsal-middle cuneiform fusions. (G) The 3-month oblique radiograph showing good graft incorporation and realignment of the foot.

assessment. A select group of 50 with multiple comorbidities was collected.⁵⁸ In this study, BMC was used for complex lower-extremity reconstructions in high-risk patients as defined by multiple comorbidities and poor local healing factors. Patients were consented preoperatively for an institutional review board–approved BMC cellular and growth factor analysis study, and institutional review board approval was obtained for retrospective analysis. Preoperative conditions included one or more of the following: acute trauma, chronic trauma, arthritis, tendon rupture, deformity, fracture, Charcot, infection, and instability. Patients had local or systemic comorbidities (average, 3.5) and conditions (average, 2.9). The most common procedures performed were arthrodesis (33 patients) and revision or nonunion repair (21 and 20 patients, respectively). The bones treated were talus,⁴⁰ tibia,²⁴ metatarsals,¹⁶ and fibula,¹³ often with their adjacent joints. The BMC was used to augment allograft DBM, femoral head allograft, and autograft or autograft/DBM mixture. Additionally, BMC was injected into the grafting site in 8 patients. Postoperative symptoms and complaints (eg, pain, swelling, stiffness, foot dysfunction, and gait limitations) were significantly lower than preoperatively (2.2 ± 2.6 vs 8.0 ± 2.7 , $P < .001$) and the use of bracing (10 vs 40 patients, $< .001$) or other support, such as a wheelchair or walker (10 vs 27 patients, $< .001$), was also lower. One patient died and therefore was lost to follow-up. After the initial reconstructive procedure, radiographic union was determined in 88% of patients. One patient reported prolonged pain at the bone marrow aspiration site (iliac crest) that resolved at 10 days postoperatively. There were no infections or wound complications related to the BMC harvest site. It was concluded that in selected high-risk patients because of local or systemic conditions, the use of autologous BMC to augment bone grafting was safe. The effect of BMC in patient outcomes could not be isolated, but there was a significant improvement in comorbidities and the use of bracing or other support after surgical treatment with the use of adjuvant BMC (Fig. 6).

PRP/BMC is used in our current practice as an adjunct to treat a broad spectrum of foot and ankle pathology. In our group of 634 patients treated, we have reviewed the diagnosis. Included are Achilles tendon rupture (20 patients), Achilles tendonopathy (midsubstance, 12 patients; insertional, 7 patients), avascular necrosis (9 patients) (navicular and talus), fracture (81 patients [ankle, calcaneous (16 patients), midfoot, metatarsal, pilon, sesamoid, talus, tibia, and lisfranc]), malunion (15 patients [ankle, forefoot, hind foot, midfoot, and talus]), nonunion (56 patients [forefoot, metatarsal, ankle, midfoot, navicular, hindfoot, talus, and tibia]), delayed union (6 patients [ankle, tibia, midfoot, forefoot, and hindfoot]), tendonosis (82 patients [peroneal tendons, extensor digitorum longus tendon, deltoid ligament, metatarsalphalangeal joint capsule, tibialis anterior, tibialis posterior, and plantar fascia]), reconstruction (344 patients [ankle, forefoot, midfoot, and hindfoot]), and wounds (2 patients).

We have encountered few complications related to the use of PRP/BMC. Five patients of the 634 have had a painful

donor site that resolved between 7 and 40 days. There were no other donor-site complications (ie, infection, wound healing problems, drainage, hernia, nerve damage, or scar pain). Of the 50 patients in the comorbidity study, there was 1 patient with a delayed union and 4 patients with nonunions. The delayed union of a triple arthrodesis went on to solid union after drilling, exchange of screws, and repeat BMC. The nonunions entailed 1 tibiototalcalcaneal arthrodesis, 1 hindfoot reconstruction, 1 navicular fracture, and 1 talus fracture. All patients successfully united with revision surgery.

In comparison, a nonunion rate of 35% (14/40 feet) was reported in a group of patients with pre-operative diagnosis of a nonunion or deemed at high risk for nonunion using an implantable bone stimulator.⁵⁹ Additionally, the authors (including LCS [senior author]) reported an increased potential for complications when using the bone stimulator in the diabetic patients.²⁵ In neuropathic midfoot reconstruction, nonunion rates of 26% to 28% have been reported.^{60,61} Thus, in the higher-risk patients, BMC may be more effective than implantable bone stimulators. Further studies are warranted to assess the relative benefits further.

Conclusions

PDGF (vascular endothelial growth, transforming growth factor, fibroblast growth factor, and so on) into the injured or diseased musculoskeletal structure. When the platelet-rich product is derived from bone marrow versus that derived from peripheral blood, cellular elements (ie, MSCs, HSCs, EPCs, mononuclear cells, and various progenitor cells) are active in the concentrate. Various conditions in the foot and ankle can be treated with these adjuvants. More clinical and basic science research is warranted to determine the role of these therapeutic modalities.

References

1. Welch ZR, McKale JM, Woodell-May J: Citrate-based anticoagulant does not hinder stem cell viability and concentration from bone marrow aspirate. 54th Orthopedics Research Societies Annual Meeting, San Francisco, CA, 2008, March 2-5
2. Woodell-May JE, Ridderman DN, Swift MJ, et al: Producing accurate platelet counts for platelet rich plasma: Validation of a hematology analyzer and preparation techniques for counting. *J Craniofac Surg* 16:749-756, 2005
3. Cervelli V, Gentile P, Scioli MG, et al: Application of platelet-rich plasma in plastic surgery: Clinical and in vitro evaluation. *Tissue Eng C Methods* 15:625-634, 2009
4. Gentile P, Bottini DJ, Spallone D, et al: Application of platelet-rich plasma in maxillofacial surgery: Clinical evaluation. *J Craniofac Surg* 21:900-904, 2010
5. Papa F, Cortese A, Sagiocco R, et al: Outcome of 47 consecutive sinus lift operations using aragonitic calcium carbonate associated with autologous platelet-rich plasma: Clinical, histologic, and histomorphometrical evaluations. *J Craniofac Surg* 20:2067-2074, 2009
6. Gentile P, Bottini DJ, Spallone D, et al: Application of platelet-rich plasma in maxillofacial surgery: Clinical evaluation. *J Craniofac Surg* 21:900-904, 2010
7. Foitzik C, Staus H: Le Fort I osteotomy in atrophied maxilla and bone regeneration with pure-phase beta-tricalcium phosphate and PRP. *Implant Dent* 12:132-139, 2003

8. Thorn JJ, Sorensen H, Weis-Fogh U, et al: Autologous fibrin glue with growth factors in reconstructive maxillofacial surgery. *Int J Oral Maxillofac Surg* 33:95-100, 2004
9. Tonelli P, Mannelli D, Brancato L, et al: Counting of platelet derived growth factor and transforming growth factor-beta in platelet-rich-plasma used in jaw bone regeneration. *Minerva Stomatol* 54:23-34, 2005
10. Cervelli V, Lucarini L, Spallone D, et al: Use of platelet rich plasma and hyaluronic acid on exposed tendons of the foot and ankle. *J Wound Care* 19:188-190, 2010
11. Akingboye AA, Giddins S, Gamston P, et al: Application of autologous derived-platelet rich plasma gel in the treatment of chronic wound ulcer: Diabetic foot ulcer. *J Extra Corpor Technol* 42:20-29, 2010
12. Almdahl SM, Veel T, Halvorsen P, et al: Randomized prospective trial of saphenous vein harvest site infection after wound closure with and without topical application of autologous platelet-rich plasma. *Eur J Cardiothorac Surg* 39:44-48, 2011
13. Knighton DR, Ciresi K, Fiegel VD, et al: Stimulation of repair in chronic, nonhealing, cutaneous ulcers using platelet-derived wound healing formula. *Surg Gynecol Obstet* 170:56-60, 1990
14. Eppley BL, Woodell JE, Higgins J: Platelet quantification and growth factor analysis from platelet-rich plasma: Implications for wound healing. *Plast Reconstr Surg* 114:1502-1508, 2004
15. Hall MP, Band PA, Meislin RJ, et al: Platelet-rich plasma: Current concepts and application in sports medicine. *J Am Acad Orthop Surg* 17:602-608, 2009. Available at: <http://www.jaaos.org>
16. Filardo G, Presti ML, Kon E, et al: Nonoperative biological treatment approach for partial Achilles tendon lesion. *Orthopedics* 33:120-123, 2010
17. Foster TE, Puskas BL, Mandelbaum BR, et al: Platelet-rich plasma: From basic science to clinical applications. *Am J Sports Med* 37:2259-2272, 2009
18. Creaney L, Hamilton B: Growth factor delivery methods in the management of sports injuries: The state of play. *Br J Sports Med* 42:314-320, 2008
19. Sánchez M, Anitua E, Lopez-Vidriero E, et al: The future: Optimizing the healing environment in anterior cruciate ligament reconstruction. *Sports Med Arthrosc* 18:48-53, 2010
20. Cheung EV, Silverio L, Sperling JW: Strategies in biologic augmentation of rotator cuff repair: A review. *Clin Orthop Relat Res* 468:1476-1484, 2010
21. Hartmann EK, Heintel T, Morrison RH, et al: Influence of platelet-rich plasma on the anterior fusion in spinal injuries: A qualitative and quantitative analysis using computer tomography. *Arch Orthop Trauma Surg* 130:909-914, 2010
22. Gaweda K, Tarczynska M, Krzyzanowski W: Treatment of Achilles tendinopathy with platelet-rich plasma. *Int J Sports Med* 31:577-583, 2010
23. Soomekh DJ: Using platelet-rich plasma in the foot and ankle. *Foot Ankle Spec* 3:88-90, 2010. Available at: <http://fas.sagepub.com/>
24. Hardy MA, Logan DB: Principles of arthrodesis and advances in fixation for the adult acquired flatfoot. *Clin Podiatr Med Surg* 24: 789-813, 2007
25. de S, de Vos RJ, Weir A, et al: One-year Follow-up of Platelet-Rich Plasma Treatment in Chronic Achilles Tendinopathy: A Double-Blind Randomized Placebo-Controlled Trial. *Am J Sports Med* 2011, May 21. [Epub ahead of print]
26. de Vos RJ, Weir A, van Schie HT, et al: Platelet-rich plasma injection for chronic Achilles tendinopathy: A randomized controlled trial. *JAMA* 303:144-149, 2010
27. Monto RR: Platelet rich plasma (PRP) effectively treats chronic Achilles tendinosis. The 77th Annual Meeting of the American Academy of Orthopaedic Surgeons (AAOS). New Orleans, LA, 2010, March 10-13
28. Gaweda K, Tarczynska M, Krzyzanowski W: Treatment of Achilles tendinopathy with platelet-rich plasma. *Int J Sports Med* 31:577-583, 2010
29. Sanchez M, Anitua E, Azofra J, et al: Comparison of surgically repaired Achilles tendon tears using platelet-rich fibrin matrices. *Am J Sports Med* 35:245-251, 2007
30. Schepull T, Kvist J, Norrman H, et al: Autologous platelets have no effect on the healing of human Achilles tendon ruptures: A randomized single-blind study. *Am J Sports Med* 39:38-47, 2011
31. Swift MJ, Welch ZR, McKale JM, et al: Efficient harvest of a mononuclear cell-rich fraction from aspirated bone marrow: 53rd Annual Meeting of the Orthopaedic Research Society. San Diego, CA, 2007, February 11-14
32. Crisostomo PR, Wang Y, Markel TA, et al: Human mesenchymal stem cells stimulated by TNF-alpha, LPS, or hypoxia produce growth factors by an NF kappaB-but not JNK-dependent mechanism. *Am J Physiol Cell Physiol* 294:C675-C682, 2008
33. Mendez-Ferrer S, Michurina TV, Ferraro F, et al: Mesenchymal and haematopoietic stem cells form a unique bone marrow niche. *Nature* 466:829-834, 2010
34. Yoshikawa T, Ueda Y, Miyazaki K, et al: Disc regeneration therapy using marrow mesenchymal cell transplantation: A report of two case studies. *Spine (Phila Pa 1976)* 35:E475-E480, 2010
35. Kitchel SH, Wang MY, Laurysen CL: Techniques for aspirating bone marrow for use in spinal surgery. *Neurosurgery* 57:286-289, 2005 (suppl)
36. McLain RF, Fleming JE, Boehm CA, et al: Aspiration of osteoprogenitor cells for augmenting spinal fusion: Comparison of progenitor cell concentrations from the vertebral body and iliac crest. *J Bone Joint Surg Am* 87:2655-2661, 2005
37. Di Bella C, Dozza B, Frisoni T, et al: Injection of demineralized bone matrix with bone marrow concentrate improves healing in unicameral bone cyst. *Clin Orthop Relat Res* 468:3047-3055, 2010
38. Wright JG, Yandow S, Donaldson S, et al: A randomized clinical trial comparing intralesional bone marrow and steroid injections for simple bone cysts. *J Bone Joint Surg Am* 90:722-730, 2008
39. Arazi M, Senaran H, Memik R, et al: Minimally invasive treatment of simple bone cysts with percutaneous autogenous bone marrow injection. *Orthopedics* 28:108-112, 2005
40. Tseng SS, Lee MA, Reddi AH: Nonunions and the potential of stem cells in fracture-healing. *J Bone Joint Surg Am* 90:92-98, 2008 (suppl 1)
41. Connolly JF: Injectable bone marrow preparations to stimulate osteogenic repair. *Clin Orthop Relat Res* 313:8-18, 1995
42. Connolly JF, Guse R, Tiedeman J, et al: Autologous marrow injection for delayed unions of the tibia: A preliminary report. *J Orthop Trauma* 3:276-282, 1989
43. Bielecki T, Gazdzik TS, Szczepanski T: Benefit of percutaneous injection of autologous platelet-leukocyte-rich gel in patients with delayed union and nonunion. *Eur Surg Res* 40:289-296, 2008
44. Bajada S, Harrison PE, Ashton BA, et al: Successful treatment of refractory tibial nonunion using calcium sulphate and bone marrow stromal cell implantation. *J Bone Joint Surg Br* 89:1382-1386, 2007
45. Hernigou P, Mathieu G, Poignard A, et al: Percutaneous autologous bone-marrow grafting for nonunions. Surgical technique. *J Bone Joint Surg Am* 88:322-327, 2006 (suppl 1)
46. Hernigou P, Poignard A, Beaujean F, et al: Percutaneous autologous bone-marrow grafting for nonunions. Influence of the number and concentration of progenitor cells. *J Bone Joint Surg Am* 87:1430-1437, 2005
47. Hernigou P, Poignard A, Manicom O, et al: The use of percutaneous autologous bone marrow transplantation in nonunion and avascular necrosis of bone. *J Bone Joint Surg Br* 87:896-902, 2005
48. Connolly JF, Guse R, Tiedeman J, et al: Autologous marrow injection as a substitute for operative grafting of tibial nonunions. *Clin Orthop Relat Res* 266:259-270, 1991
49. Healey JH, Zimmerman PA, McDonnell JM, et al: Percutaneous bone marrow grafting of delayed union and nonunion in cancer patients. *Clin Orthop Relat Res* 256:280-285, 1990
50. Pinzur MS: Use of platelet-rich concentrate and bone marrow aspirate in high-risk patients with Charcot arthropathy of the foot. *Foot Ankle Int* 30:124-127, 2009

51. Prochazka V, Gumulec J, Jaluvka F, et al: Cell therapy, a new standard in management of chronic critical limb ischemia and foot ulcer. *Cell Transplant* 19:1413-1424, 2010
52. Ishigatsubo Y, Ihata A, Kobayashi H, et al: Therapeutic angiogenesis in patients with systemic sclerosis by autologous transplantation of bone-marrow-derived cells. *Mod Rheumatol* 20:263-272, 2010
53. Giannini S, Buda R, Vannini F, et al: One-step bone marrow-derived cell transplantation in talar osteochondral lesions. *Clin Orthop Relat Res* 467:3307-3320, 2009
54. Courneya J-P, Luzina IG, Orlov MD, et al: Bone marrow stem cells heal tendon via secreted factors: World Stem Cell Summit, Baltimore, MD, 2009, September 21-23
55. Chong AK, Ang AD, Goh JC, et al: Bone marrow-derived mesenchymal stem cells influence early tendon-healing in a rabbit Achilles tendon model. *J Bone Joint Surg Am* 89:74-81, 2007
56. Han SH, Lee JW, Guyton GP, et al: Leonard Goldner Award 2008. Effect of extracorporeal shock wave therapy on cultured tenocytes. *Foot Ankle Int* 30:93-98, 2009
57. Han B, Woodell-May J, Ponticello M, et al: The effect of thrombin activation of platelet-rich plasma on demineralized bone matrix osteoinductivity. *J Bone Joint Surg Am* 91:1459-1470, 2009
58. Schon LC, Gamez L, Dunn R: Cell concentrate from autologous bone marrow augments bone grafting in the lower extremity. American Orthopaedic Foot and Ankle Society 26th Annual Summer Meeting, National Harbor, MD, 2010 July 7-10
59. Lau JT, Stamatis ED, Myerson MS, et al: Implantable direct-current bone stimulators in high-risk and revision foot and ankle surgery: A retrospective analysis with outcome assessment. *Am J Orthop (Belle Mead NJ)* 36:354-357, 2007
60. Sammarco VJ, Sammarco GJ, Walker EW Jr, et al: Midtarsal arthrodesis in the treatment of Charcot midfoot arthropathy. Surgical technique. *J Bone Joint Surg Am* 92:1-19, 2010 (suppl 1)
61. Assal M, Stern R: Realignment and extended fusion with use of a medial column screw for midfoot deformities secondary to diabetic neuropathy. *J Bone Joint Surg Am* 91:812-820, 2009