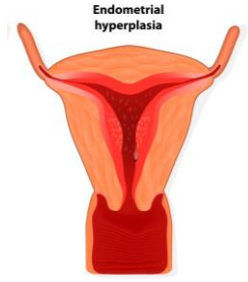


WHTA Mini-Tutes 2014

Introduction to Endo-Anal Ultrasound



PURPOSE OF MINI-TUTE

This mini-tute is designed to assist physiotherapists in identifying the anatomy and interpreting the images obtained from endo-anal ultrasound. Focus will be placed on identifying the anal mucosa, internal and external anal sphincter, as well as the importance of considering the location (depth) along the anal canal in which the image was taken before assessing for dysfunction.

TOPICS

- Brief Review of Anorectal Anatomy
 - o Anal Canal vs Rectum including anorectal junction
 - o Dentate line
 - o Somatic vs Visceral Innervation
 - o Location of External vs Internal Anal Sphincter vs Puborectalis
- Appearance of smooth vs striated muscle on endo-anal ultrasound
- Commonly identified defects / asymmetries on EA-US

DURATION **9min 11sec**

LINK <https://www.educreations.com/lesson/view/endo-anal-ultrasound-review/26663724/?s=NqGHOX&ref=appemail>